COMPARATIVE EVALUATION OF THE OF DIFFERENT FRACTIONATION MEDIA OF MALE CARICA PAPAYA MALE TREE BARK EXTRACT ON TESTICULAR FUNCTION IN MALE SPRAGUE-DAWLEY RAT

[1]Adeoye F.Oyeyemi.; [2]Bakare A.Adeola.;[3]Olayinka A.Temitayo.; [4]Opadokun N.Abiola.; [5]Ugwu Marta.; &[6]Kusemiju T.Olabisi

[1]Department of Anatomy, Faculty of Basic Medical Sciences, Federal University of Medicine and Medical Sciences Abeokuta, Nigeria

[2,5,6]Department of Anatomy, Faculty of Basic Medical Sciences, College of Medicine, University of Lagos, Nigeria

[3]Department of Anatomy, Faculty of Basic Medical Sciences, Kampala International University, Ishaka, Uganda

4 Department of Human Anatomy, School of Medicine and Health Sciences, Kenya Methodist University, Kenya.

***Author for Correspondence:**

Bakare A. A

Email: aabakare@unilag.edu.ng

ABSTRACT

Traditional use of Carica papaya for disease management necessitates scientific validation regarding the effects of different extraction media on bodily functions, particularly the reproductive system, hence this study investigated the effects of different Carica papaya bark extraction media (N-hexane, dichloromethane, ethyl acetate, and butanol) on endocrine regulation and the testis histo-architecture in male rats. Dried male Carica papaya bark powder was purified with petroleum ether, then subjected to sequential extraction to obtain N-hexane (CPFN), dichloromethane (CPFD), ethyl acetate (CPFE), and butanol (CPFB) extracts. Twenty-five male rats were divided into five groups (n=5). Groups B, C, D, and E received 75 mg/kg body weight of CPFN, CPFD, CPFE, and CPFB, respectively, for 4 weeks. Group A received distilled water (control). After 4 weeks, animals were euthanized. Testes were weighed and processed for histological evaluation. Serum levels of testosterone (TT), luteinizing hormone (LH), and follicle-stimulating hormone (FSH) were assayed using ELISA. **Findings showed that t**he N-hexane (CPFN) group exhibited significant detrimental effects: marked coagulative necrosis of seminiferous tubules, reduction in spermatogenic cell series, and a significant decrease in serum TT level accompanied by a relative decrease in LH and FSH levels, compared to the other extraction media groups. The findings suggest that the N-hexane fraction of Carica papaya bark extract possesses characteristics capable of inducing male infertility. This effect is likely due to residual compounds that impair sperm production, hormonal balance, and overall reproductive function. The use of this specific extract in natural medication warrants caution.

Keywords: Carica Papaya, N-hexane, Butanol, Testosterone, Testis

INTRODUCTION

Reproduction is one of the most important necessity of life, quintessential to increasing the number of populations, minimizing the risk of extinction through replacement of dead ones, and also helping to bring about evolution through variation (Gomez, 2021). Reproduction in males has stirred global concerns over its high susceptibility to harmful influences, such as; oxidative stress, drugs, and toxins, which have been reported to inhibit the process of spermatogenesis (Cocuzza *et al*., 2008; Nicolo *et al*., 2022). Male reproduction is hormonally driven, and the actions of different reproductive hormones regulating its processes when exerted along the hypothalamic-pituitary-gonadal (HPG) axis bring about the production of mature and viable male sex gametes in the seminiferous tubules of the testis. (Bukharin *et al*., 2000; Hiba *et al*., 2022). However, the accomplishment of this hormone-driven process leading to the production of healthy spermatozoa is often disrupted by the activities of some external chemicals which act to mimic, block, or alter the actions of the actual reproductive hormones from eliciting their actions at their target site with their respective receptors. Hence, causing dysfunctionality along the HPG axis, which resultantly leads to impairment in the functional and structural integrity of the male reproductive organs (Bukharin *et al*., 2000).

Histology is crucial in establishing evident structural changes in the testis and has been used in *the*assessment of testicular function. Microscopic examinations of seminiferous tubules, Sertoli cells, Leydig cells, blood capillaries, and tunica albuginea have been examined and used to establish effects of test substances by researchers (Ayse and Şadiye, 2022). Histopathologists have used histological changes of the Sertoli cell, which plays significant roles in preserving the structural integrity of seminiferous epithelium and production of mature sperm cells (Johnson, 2015). Endocrine regulations are important for normal spermatogenesis. These endocrine hormones mainly entail testosterone, luteinizing hormone and follicle-stimulating hormone. Testosterone (TT) is the primary male hormone responsible for the initiation and control of spermatogenesis. Luteinizing hormone (*LH)* stimulates Leydig cells that are located in the interstitial spaces around the seminiferous tubules of the testes to produce testosterone through the process of steroidogenesis. Follicle-stimulating hormone (FSH) is required to nourish the developing sperm cells. LH and FSH are gonadotropins produced by the pituitary gland, which are intermittently released into the blood stream in response to their physiological need at thresholds appropriate for qualitative and quantitative sperm production (Walker, 2011). More specifically, s*permatogenesis* involves the coordination of a number of molecular *signaling* pathways in the testes in response to hormone stimulations from the LH and FSH (Smith and Walker, 2014; Sengupta *et al*., 2019). Studies on abnormal gonadotropin levels enhance in-depth understanding of male gonadal physiology and actions of hormones at their target sites (Lottini *et al*., 2021). An investigation carried out in rodents showed that absence of FSH-receptor action sites significantly decreased sperm quality, and this was attributed to reduction in the number of Sertoli cells and their insufficiency to nurture germ cells to attain full maturity (Wreford *et al*., 2001; Abel *et al*., 2008). This shows that regulated levels of hormones are primary and of immense importance for adequate ligand-receptor activations at the receptor binding sites. Comparable submissions from the body of scientific literature have attributed the ultimate role of LH in spermatogenesis to the induction of intratesticular testosterone production. Findings from one of the studies, conducted using LH-receptor knockout mice models, showed a reduction in the TT profile with marked impairment or distortion in spermatogenesis, however, restored following testosterone replacement therapy.(Lei *et al*., 2001; Oduwole *et al*., 2014).

Carica papaya (C. papaya), commonly referred to as pawpaw, is an important fruit crop cultivated in tropical regions. It belongs to the genus Carica, family Caricaceae (Badillo *et al*., 2000). *C.*papaya is known for its nutritional benefits and numerous medicinal uses. As a matter of fact, different parts of the pawpaw plant have been used to treat many diseases. It has been traditionally used in the management of ulcers, malaria, diabetes, cancer, and neurological disorders, among others (Vij and Prashar, 2015; Adeoye and Bakare, 2024). These medicinal effects have been scientifically proven and attributed to its antioxidative properties. It has been *confirmed to have* a protective effect against diabetes. The leaf ethanolic extract was reported to reduce blood glucose level in alloxan-induced diabetic rats (Tridiganita, 2020). Another study reported its protective effect on platelets by inhibiting the progression of oxidative damage associated with diabetes (Raffaelli *et al*., 2014).

Fermented papaya preparation has been shown to be a promising ameliorative agent in Alzheimer's disease where a reduction in 8-hydroxy2'-deoxyguanosine level was seen in treated subjects (Barbagallo *et al*., 2015). In reproduction, the extracts of the seed and leaf parts of the *C.* papaya plant using different sources of extraction have been suggested to exhibit antifertility effects. The methanolic seed extract was reported to reduce reproductive performance through decreased gonadosomatic index (Radwan, 2023).The crude aqueous seed also showed reduction in sperm motility associated with structural defects, reduced sperm count, and decreased testicular weight (Lohiya, 1994). More so, the methanolic leaf extract showed severe necrosis of germinal epithelium (Chinaka, 2013). Even though the seed and leaf parts of the *C.* papaya plant with different extraction media have shown anti-fertility effects, the choice of extraction solvent is important in extracting bioactive compounds from this natural product (Soib *et al*., 2020). Therefore, this present study aimed to investigate the effects of the different fractions of the bark extracts of *C.* papaya on reproductive hormones and their impacts on testicular histoarchitecture

MATERIALS AND METHODS

Plant material

Collection and Preparation of Carica papaya (CP) Extracts: The bark of the Carica papaya plant was chopped down using a cutlass from a pawpaw tree plantation in Lagos and authenticated in the Department of Botany, University of Lagos, by Mr. Nodza Gorge, a taxonomist in the Department of Botany, University of Lagos, Nigeria, with herbarium number 100312.

Preparation of CPFN, CPFD, CPFE and CPFB extraction media

The bark of the CP tree was dried in an electric oven at 40°C for 4 days and crushed to obtain a coarse powder that was used for the extraction in the Department of Pharmacognosy, Faculty of Pharmacy, University of Lagos. 200 g of the powder was dissolved into 1000 ml of water. The solution was fractionated using petroleum ether chloroform: ethyl acetate (8:2) and ethyl acetate: methanol (3:7) as eluents. Following partial purification, the petroleum ether fraction was further subjected to N-hexane, Dichloromethane, Ethyl-acetate, and Butanol media, then through thin-layer chromatography to obtain CPFN, CPFD, CPFE, and CPFB extracts respectively (Babalola, 2019).

Experimental design

Twenty-five male Sprague-Dawley rats weighing 100 g - 130 g were used in this experiment. The animals were procured from the animal house of the College of Medicine, University of Lagos, Idi-Araba, and kept in well-ventilated cages under a room temperature of a 12-hour light-dark cycle. Rat pellets and clean water were provided ad libitum. The animals were subjected to two weeks' acclimatization to laboratory conditions before experimentation. The animals were divided into five study groups, A, B, C, D, and E of five animals each. CPFN, CPFD, CPFE, and CPFB fractions were administered daily to groups B, C, D, and E at a dose of 0.75 ml of 75 mg/kg, respectively (Babalola, 2019) while group A received the equal volume of distilled water. All administrations were done orally for 4 weeks. The five groups were subjected to the same feeding regimen, and at the end of the 4 weeks' experimental period, animals were sacrificed, testes of the control and experimental rats were removed for histological processing. Blood samples were also collected through the left ventricular cardiac puncture for hormone profile analysis. This research was carried out in the animal house of the Department of Anatomy, Faculty of Basic Medical Sciences, College of Medicine, University of Lagos. The study was done in accordance with internationally accepted principles for laboratory investigations and complied with institutional guidelines for the care and use of animals for experimentation (ACUREC, 2011).

Tissue processing for histoarchitecture of the testis

The fixed testicular tissues were transferred into ascending grades of alcohol, then passed through three grades of absolute alcohol for one hour each, and finally cleared in xylene. The tissues were then infiltrated in molten paraffin wax. Serial sections were obtained from the solidified paraffin

block of tissue using the rotary microtome and floated in a water bath. The sections were picked with clean slides onto which egg albumin had been coated and dried. The mounted sections were de-waxed in xylene and then hydrated in descending grades of alcohol. The mounted sections were then stained with Hematoxylin and counterstained in Eosin (Mohamed and Laurence, 2011).

Hormonal Assays for Testosterone (TT), Luteinizing hormone (LH) and Follicle stimulating hormone (FSH)

The serum samples were collected and assayed for TT, LH, and FSH in comparison with the control group by standard qualitative enzyme linked immunosorbent assay (ELISA) technique with Microwell Kit from Syntrobioresearch Inc., California, U.S.A. 10µl of standard sample and control were dispensed into desired number of coated wells. 100 µl of conjugated reagent was dispensed into each well. The contents of the well were mixed vigorously for 30 seconds and incubated for 90 min at room temperature. Later, the wells were washed with distilled-deionized water. 100 µl of hormone binding reagent was dispensed into each well and incubated for 20 mins. Reaction at this level was established and color intensity measured on a micro well automatic reader (Osinubi *et al*., 2007).

Statistical analysis

The data obtained from the hormone profiles of CPFN, CPFD, CPFE, CPFB and the control animals were analyzed using GraphPad Prism statistical software version 8.0 and are expressed as mean ± SD (standard deviation). Comparison of statistical differences between groups was conducted using analysis of variance (ANOVA), followed by Scheffe's post-hoc test and the p-value of $p < 0.01$ was taken to imply statistical significance.

RESULTS

Effects of the different extraction media on histology of the testes

The microscopic presentation of the control testicular tissue showed well-defined seminiferous tubules containing normal spermatogenic series as shown in figure 1. The administration of N-Hexane (CPFN) fraction for 4 weeks showed significant alteration in the histology of the testis as shown in figure 2. In this section, marked coagulative necrosis of seminiferous tubules and reduction in spermatogenic series, lining cells and luminal spermatozoa were seen. While the dichloromethane (CPFD), ethyl acetate (CPFE), and butanol (CPFB) groups showed no significant alterations in the histology of the testis that were comparable with the control group, as shown in figure 3,4, and 5. In these sections, the testis showed seminiferous tubules containing germ cells and normal amounts of spermatogenic series, lining cells, and luminal spermatozoa.

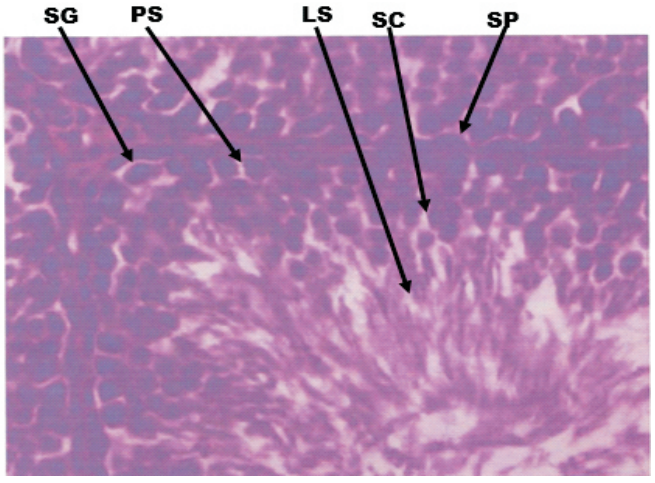

Figure 1: Photomicrograph of the testis of the control group showing normal progression in spermatogenesis. H and E X400. SG: Spermatogonium, PS: Primary Spermatocyte; SP: Spermatid; SC: Sertoli cells; LS: Luminal spermatozoa indicating abundance in spermatozoa development in the seminiferous tubule.

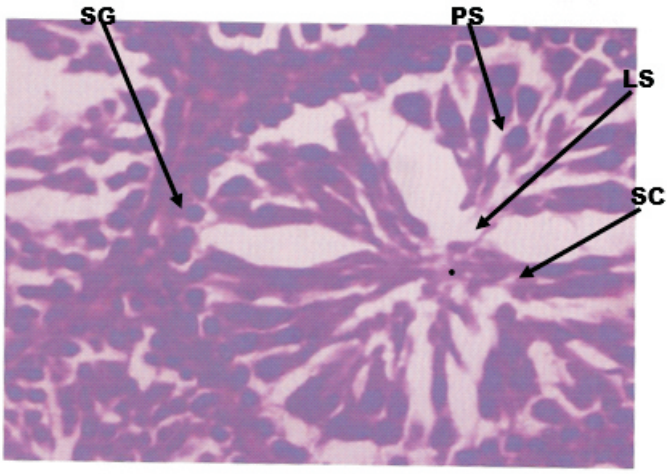

Figure 2: Photomicrograph of the testis of CPFN extract treated group showing necrosis and cell depletion of the spermatogenic cell population. H and E X400.SG: Spermatogonium; PS: Primary Spermatocyte; SC: Sertoli cells; LS: luminal spermatozoa (very scanty)

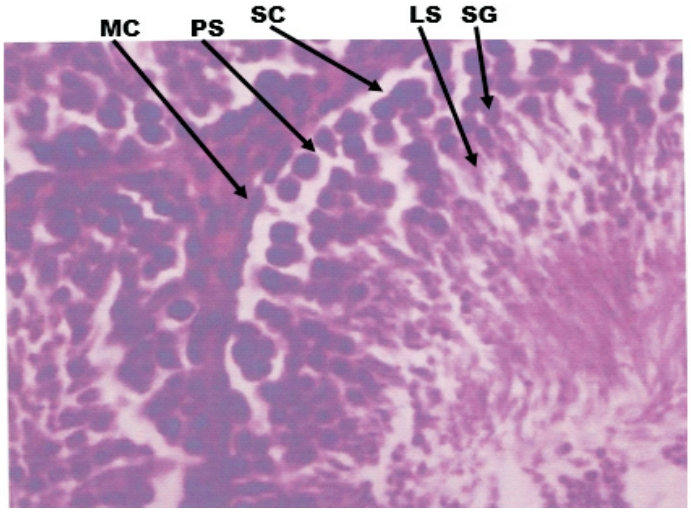

Figure 3: **Photomicrograph of the testis of CPFD extract treated group. H and E X400.**SG: Spermatogonium; PS: Primary Spermatocyte; SC: Sertoli cells; LS: luminal spermatozoa; MC: Myoid cells

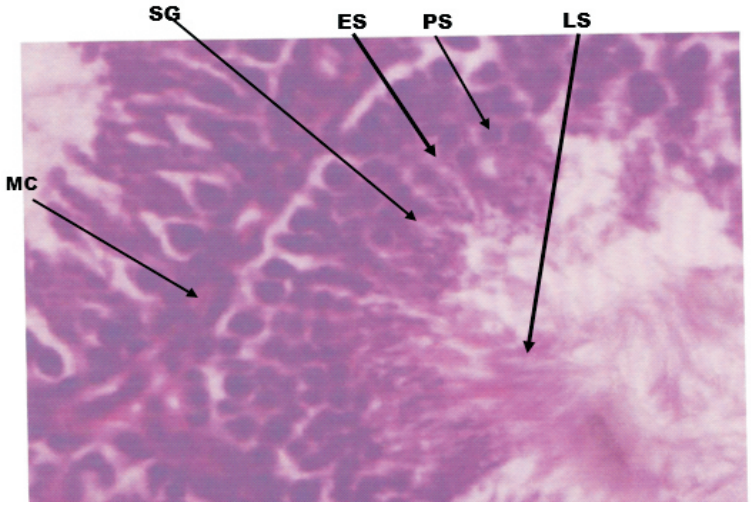

Figure 4: **Photomicrograph of the testis of CPFE extract treated group. H and E X400.**PS: Primary Spermatocyte; ES: Early Spermatids; LS: Late spermatids; SG: Spermatogonium; MC: Myoid cells

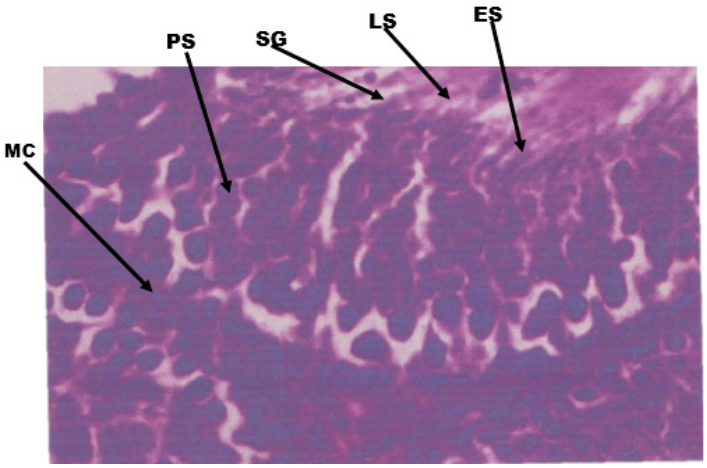

Figure 5: Photomicrograph of the testis of CPFB extract treated group. H and E X400. SG: Spermatogonium; PS: Primary Spermatocyte; ES: Early Spermatids; LS: Late spermatids and MC: Myoid cells.

Effects on testicular weight

There is no significant difference in the relative testicular weights of animals in the CPFE and CPFD groups when compared to the control group after four weeks of administration. However, the CPFN and CPFB groups showed significant difference in testicular weight in comparison with the control group. The CPFN group shows more significant difference in testicular weight as shown in table 1.

Table 1: Showing testicular weights of the different extraction media of C. papaya.

GROUP	TESTICULAR WEIGHT OF MEAN ± SD
Control	3.55± 0.18
CPFB (Butanol)	3.25± 2.03*
CPFE (E. Acetate)	3.54±0.12
CPFD (Dichloromethane)	3.56±1.02
CPFN (N-Hexane)	3.10±2.11***

Values are represented in Mean ± SD.

*** indicates high level of significant decrease of Mean ± SD value of experimental groups in comparison with the control group.

+++ indicates high level of significant increase of Mean ± SD value of experimental groups in comparison with the control group.

Effects on reproductive hormones

There was significant reduction in serum LH levels in all extraction media with most significant reduction noted in the CPFB and CPFE groups. More so, significant reduction in FSH levels were seen only the CPFB and CPFN groups. The level of TT was significantly low in the CPFN group when compared to the other extraction media and the control group as shown in table 2 below.

Table 2: Showing the effects of different fractions of C. papaya. on serum LH, FSH and TT levels.

GROUP	LH	FSH	TT
CONTROL	4.6±0.06	3.73±0.20	0.58±0.12
CPFB (Butanol)	2.1±0.06***	2.80±0.46**	0.59±0.30
CPFE (E. Acetate)	2.3±0.17***	3.30±0.12	1.22±0.01
CPFD (Dichloromethane)	3.5±0.17*	4.10±0.58+	0.75±0.58
CPFN (N-Hexane)	2.8±0.35***	3.00±0.23*	0.39±0.04**

Values are represented in Mean ± SD.

*** indicates high level of significant decrease of Mean ± SD value of experimental groups in comparison with the control group.

DISCUSSION

Carica papaya is a well-known therapeutic and nutritional natural plant product all over the world. Different parts of the plant, including the leaves, seeds, trunk, and fruits, have been used as traditional remedies to manage various oxidative stress-related health conditions due to their high phytochemical contents and antioxidant activity (Yew *et al*., 2021). However, more scientific investigations are needed to establish the potential effects of different media of extraction and their impacts in the body before exploring their application in the treatment of diverse health conditions. Even though different fractions of extracts of the seed and leaf of C. papaya have been reported to exert different effects (Bagus, 2012).This present study showed distortion of testicular histology, cell necrosis, reduction in testicular weight and reproductive hormones (TT, LH and FSH) by N-hexane fraction of C. papaya male tree bark extract.

Aqueous extract of the bark of C. papaya was previously said to have deleterious effects on both the seminiferous tubules and testicular interstitium (Kusemiju *et al*., 2010). Additionally, the findings from our studies on hormone profiles conform with a previous study on N-hexane seed extract of C. papaya, which showed a marked reduction in the mean number of testicular cells: spermatogonia A, spermatocyte, spermatid, Sertoli, and Leydig cells (Nur, 2019; Christin and Young, 2022).

Hormonal interplay between TT, LH, and FSH is the bedrock of spermatogenesis, and this translates into structural effects on testicular histology used to gauge normal spermatogenesis. The release of gonadotropin-releasing hormone by the hypothalamus stimulates the production of LH and FSH by the pituitary gland. LH stimulates Leydig cells to produce testosterone, an androgen required for initiating and maintaining spermatogenesis while FSH acts on the Sertoli cells to nourish and provide blood products needed to enhance maturation (Giuseppe *et al*., 2022; Jia *et al*., 2022). This study confirms the connection between the male reproductive hormones and testicular histology, as some fractions of C. papaya male tree bark extracts specifically, the CPFN caused a significant decrease in the hormone thresholds and relative distortion in the testicular histology, cell necrosis and depletion. This finding indicates that male reproductive hormone controls spermatogenesis, as it further establishes a correlation tendency that a decrease in the production ratio of the hormones will translate to distortion in the histological and structural integrity of the seminiferous epithelium and production of sperm cells. Testicular weight is a function of the number of germ cells; hence the reduction in testicular weight noticed in this study can be attributed to the depletion effect of the N-hexane fraction on the number of spermatogenic cells.

CONCLUSION

The CPFN fraction of the male C. papaya bark extract significantly affects the testis in the short-term period of administration of 4 weeks with marked effects on the histoarchitecture of the testis, testicular weight, and reproductive hormones. The N-hexane fraction of C. papaya bark extract demonstrated depletion that may not only hinder the production of mature and viable male gametes but also affect fertility status. Therefore, the usage of C. papaya N-hexane extract for medicinal and nutritional purposes should be under strict control and monitoring. More importantly, continuous global attention should be given to the male reproductive system with keen surveillance on agents that can inhibit endocrine secretions leading to hormone impairments that can affect the process of spermatogenesis and consequently infertility. Therefore, it is recommended that further studies be carried out on hormone gene expressions for more comprehensive understanding.

AUTHORS' CONTRIBUTION

Investigation, data collection and manuscript writing by Adeoye O.F. Conceptualization, data analysis, data interpretation and manuscript writing by Adeoye O.F, Kusemiju T.O and Bakare A.A;Critical review and manuscript writing by Adeoye O.F , Bakare A.A, Abdulkareem T.O, Ugwu M. and Opadokun N.A.

ACKNOWLEDGEMENT

We acknowledge the support from the Department of Anatomy, College of Medicine, University of Lagos for providing the laboratory space for this research. We also acknowledge the Department of Biochemistry for providing the required chemicals and fractionation apparatus for this study.

CONFLICT OF INTEREST

None

FUNDING

Funding was not received for this study.

REFERENCES

Abel, M. H., Baker, P. J., Charlton, H. M., Monteiro, A., Verhoeven, G., & De Gendt, K. (2008). Spermatogenesis and Sertoli cell activity in mice lacking Sertoli cell receptors for follicle-stimulating hormone and androgen. *Endocrinology, 149*(7), 3279–3285.

Adeoye, O. F., & Bakare, A. A. (2024).Comparative study on the contraceptive effects of butanol and dichloromethane fractions of *Carica papaya* male tree bark in male Sprague-Dawley rats.*Journal of Experimental and Clinical Anatomy, 21*(2), 163–167.

Animals Care and Use Research Ethics Committee (ACUREC). (2011). *Guide for the care and use of laboratory animals* (8th ed.).

Ayse, B. A., & Şadiye, K. (2022). The effect of vitamin E on testicular histology and antioxidant level in rats exposed to bisphenol A. *Animal Health, Production and Hygiene, 11*(2), 21–29.

Babalola, B. (2019). *Extraction, purification and characterization of papain enzyme from the leaves of Carica papaya (EC. 3(4)22.2).*Mountain Top University, Ogun State, Nigeria.

Badillo, V. M., Carica, L., & Vasconcella, S. (2000). (Caricaceae) con la rehabilitación de este último. *Ernstia, 10*, 74–79.

Barbagallo, M., Marotta, F., & Dominguez, L. J. (2015). Oxidative stress in patients with Alzheimer's disease: Effect of extracts of fermented papaya powder. *Mediators of Inflammation, 2015*, 624801. https://doi.org/10.1155/2015/624801

Bukharin, O. V., Kuzmin, M. D., & Ivanov, I. B. (2000).The role of the microbial factor in the pathogenesis of male infertility.*Zhurnal Mikrobiologii, Epidemiologii i Immunobiologii, 2000*, 106–110.

Chinaka, N. (2013). Anti-fertility effects of *Carica papaya* Linn: Methanol leaf extracts in male Wistar rats. *Journal of Pharmacology and Toxicology, 8*(1), 35–41.

Christin, M. S., & Young, J. (2022).Androgens and spermatogenesis.*Annales d'Endocrinologie (Paris), 83*(3), 155–158. https://doi.org/10.1016/j.ando.2022.04.010

Cocuzza, M., Athayde, K. S., Agarwal, A., Pagani, R., Sikka, S. C., & Lucon, A. M. (2008). Impact of clinical varicocele and testis size on seminal reactive oxygen species levels in a fertile population: A prospective controlled study. *Fertility and Sterility, 90*(4), 1103–1108.

Giuseppe, G., Ferran, B., Ada, S., Meritxell, J., Francesca, M., & Riccardo, M. (2022). The role of testosterone in spermatogenesis: Lessons from proteome profiling of human spermatozoa in testosterone deficiency. *Frontiers in Endocrinology, 13*, 852661. https://doi.org/10.3389/fendo.2022.852661

Gomez-Marquez, J. (2021). What is life? *Molecular Biology Reports, 48*(8), 6223–6230.

Hiba, H., Sudhanshu, B., Monika, F., & Andreas, M. (2022). Mechanism of inflammatory associated impairment of sperm function, spermatogenesis and steroidogenesis. *Frontiers in Endocrinology, 13*, 897029. https://doi.org/10.3389/fendo.2022.897029

Jia, M. W., Zhen, F. L., Wan, X. Y., & Fu, Q. T. (2022). Follicle-stimulating hormone signaling in Sertoli cells: A licence to the early stages of spermatogenesis. *Reproductive Biology and Endocrinology, 20*, 97.

Johnson, K. J. (2015). Testicular histopathology associated with disruption of the Sertoli cell cytoskeleton. *Spermatogenesis, 4*(2), e979106.

Kusemiju, T. O., Osinubi, A. A., Noronha, C. C., & Okanlawon, A. O. (2010).Effect of aqueous extract of the bark of *Carica papaya* on testicular histology in Sprague-Dawley rats.*Nigerian Quarterly Journal of Hospital Medicine, 20*(3), 133–137.

Lei, Z. M., Mishra, S., Zou, W., Xu, B., Foltz, M., & Li, X. (2001).Targeted disruption of luteinizing hormone/human chorionic gonadotropin receptor gene.*Molecular Endocrinology, 15*(1), 184–200. https://doi.org/10.1210/mend.15.1.0586

Lohiya, N. K., Goyal, R. B., Jayaprakash, D., Ansari, A. S., & Sharma, S. (1994). Antifertility effects of aqueous extract of *Carica papaya* seeds in male rats. *Planta Medica, 60*(5), 400–404.

Lottini, T., Iorio, J., Lastraioli, E., Carraresi, L., Duranti, C., & Sala, C. (2021). Transgenic mice overexpressing the LH receptor in the female reproductive system spontaneously develop endometrial tumour masses. *Scientific Reports, 11*, 8847. https://doi.org/10.1038/s41598-021-87492-5

Mohamed, S., & Laurence, F. (2011). Histopathology procedures: From tissue sampling to histopathological evaluation. *Drug Safety Evaluation, 691*, 69–82.

Nicolo, S., Stefania, C., Alessio, M., Andrea, M., Maria, C. S., & Mauro, P. (2022). Recreational drug misuse and its potential contribution to male fertility decline: A narrative review. *Brain Sciences, 12*(11), 1582. https://doi.org/10.3390/brainsci12111582

Nur, L. D. H. (2019). Antifertility effect of N-hexane, ethyl acetate and water fractions from *Carica papaya* leaves on sperm motility in male Wistar rats. *Advances in Health Sciences Research, 26*, 155–158.

Oduwole, O. O., Vydra, N., Wood, N. E., Samanta, L., Owen, L., & Keevil, B. (2014). Overlapping dose responses of spermatogenic and extragonadal testosterone actions jeopardize the principle of hormonal male contraception. *FASEB Journal, 28*(6), 2566–2576. https://doi.org/10.1096/fj.13-249219

Osinubi, A. A., Daramola, A. O., Noronha, C. C., Okanlawon, A. O., & Ashiru, A. O. (2007). Effect of quinine and ascorbic acid on rat testes.*West African Journal of Medicine, 26*(3), 217–221.

Radwan, M., Darweesh, K. F., & Ghanem, S. F. (2023). Regulatory roles of pawpaw (*Carica papaya*) seed extract on growth performance, sexual maturity, and health status with resistance against bacteria and parasites in Nile tilapia (*Oreochromis niloticus*). *Aquaculture International, 17*(24), 06.

Raffaelli, F., Nanetti, L., Montecchiani, G., Borroni, F., Salvolini, E., & Faloia, E. (2014). In vitro effects of fermented papaya (*Carica papaya* L.) on platelets obtained from patients with type 2 diabetes. *Nutrition, Metabolism and Cardiovascular Diseases, 25*(2), 224–229.

Sengupta, P., Arafa, M., & Elbardisi, H. (2019).*Molecular signaling in spermatogenesis and male infertility*.CRC Press. ISBN: 9780367199302

Smith, L. B., & Walker, W. H. (2014).The regulation of spermatogenesis by androgens.*Seminars in Cell and Developmental Biology, 30*, 2–13. https://doi.org/10.1016/j.semcdb.2014.02.012

Soib, H. H., Ismail, H. F., Ya'akob, H., Idris, M. K., & Abd'Aziz, A. (2020). Effect of extraction solvents on antioxidant and wound healing properties of *Carica papaya* leaves extract. *Food Research, 4*(2), 76–83.

Tridiganita, I. S., Boedi, S., & Dilian, R. I. (2020). Antidiabetic activity of papaya leaf extract (*Carica papaya* L.) isolated with maceration method in alloxan-induced diabetic mice. *Systematic Reviews in Pharmacy, 11*(9), 774–778.

Vij, T., & Prashar, Y. A. (2015). Review on medicinal properties of *Carica papaya* Linn. *Asian Pacific Journal of Tropical Disease, 5*(1), 1–6.

Walker, W. H. (2011). Testosterone signaling and the regulation of spermatogenesis.*Spermatogenesis, 1*(2), 116–120. https://doi.org/10.4161/spmg.1.2.15275

William, H. W., & Paul, S. C. (2023).Functions of steroid hormones in the male reproductive tract as revealed by mouse models.*International Journal of Molecular Sciences, 24*(3), 2748.

Wreford, N. G., Rajendra, K. T., Matzuk, M. M., & de Kretser, D. M. (2001).Analysis of testicular phenotype of follicle-stimulating hormone beta-subunit knockout and activin type II receptor knockout mice by stereological analysis.*Endocrinology, 142*(7), 2916–2920.

Yew, R. K., Yong, X. J., Manisha, B., Zhui, K. B., Janice, K. K., & Kai, C. T. (2021). Beneficial role of *Carica papaya* extracts and phytochemicals on oxidative stress and related diseases: A mini review. *Biology (Basel), 10*(4), 287.

Zarate, & Bagus, K. S. (2012). Fractions of the hexane extract of young *Carica papaya* seeds can inhibit spermatogenesis in male mice more than fractions of the methanol extract. *Indonesian Journal of Biomedical Sciences, 2*(1), 51–57.